

PATIENT PRESENTING CLINICAL SIGNS

Possible CHF

SPECIES ULTRASONOGRAPHIC EXAMINATION OF THE HEART

Canine

BREED

Dachshund Mix

SEX

Spayed Female

AGE

13 years

WEIGHT

INTERPRETED BY

Lisa Carioto, DVM,
DVSc, Diplomate
ACVIM

IMAGING PERFORMED BY

Shari Reffi, CVT

HOSPITAL NAME

REFERRING VET

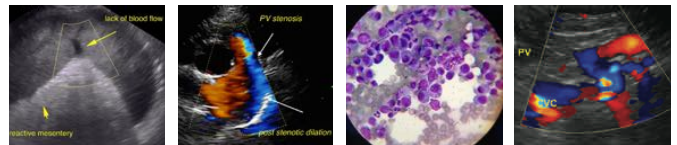
INVOICE

DATE

4/22/22

CANINE	MR	TR	LA/AO	LA/AO	FS	EF	EPSS
CARDIAC PARAMETERS	VMAX (m/s)	VMAX (m/s)	(Boon method)	(Heart Base; Swe)	(%)	(%)	(cm)
NORMAL PARAMETER	4.5-5.5	<2.7	1.3	<1.6	28-40	40-100	<0.6
PATIENT	6.18	1.4	1.24	1.43	40	72	0.25
CANINE	HR	AV	PV	BODY WEIGHT	LA	LVIDd	LVIDs
CARDIAC PARAMETERS	(BPM)	VMAX (m/s)	MAX (m/s)	kg	2D long axis Base view (cm)	Avg; 2D and m-mode short axis (cm)	Avg; 2D and m-mode short axis (cm)
NORMAL PARAMETER	50-100	0.7-1.7	0.7-1.6				
PATIENT	154	1.53	1.2	Not available	3.18	3.93	2.34

- Mild to moderate myxomatous degeneration of both leaflets. The anterior (septal) leaflet is more severely affected compared to the posterior leaflet (very mild to mild).
- Mild to moderate prolapse of the septal leaflet and very mild to mild prolapse of the posterior leaflet.
- Marked mitral regurgitation; two divergent jets.
- Marked left atrial enlargement.
- Moderate left auricular enlargement.
- Mild myxomatous degeneration of the tricuspid valve.
- Mild to moderate tricuspid regurgitation; one large jet with one very thin divergent jet.
- No right ventricular or atrial enlargement.
- Pulmonic valve, no abnormalities.
- Pulmonary veins, mildly prominent (subjective finding).



- PATIENT**
- Pulmonary artery - bifurcation, no abnormalities.
 - Pulmonary artery: aortic ratio within normal limits.
 - No signs of heartworms.
- SPECIES**
- Canine
- No signs of pericardial or pleural effusion.
 - No evidence of pulmonary edema.
- BREED**
- Dachshund Mix
- No obvious signs of a mass.

ULTRASONOGRAPHIC FINDINGS

- SEX**
- Spayed Female
- Myxomatous degeneration of the mitral valve, ACVIM stage B2.
 - There are no obvious signs of congestive heart failure based on the ultrasound findings, however, Blossom may be showing clinical signs, such as coughing due to compression of the mainstem bronchus due to left atrial enlargement.
- AGE**
- 13 years

INTERPRETATION OF THE FINDINGS & FURTHER RECOMMENDATIONS

Treatment with pimobendan is indicated and recommended based on the results of the EPIC study.

Other suggestions/recommendations include:

- Evaluation of blood pressure
- Treatment with pimobendan at 0.25-0.30 mg/kg PO every 12 hours
- Monitoring of the resting (sleeping) respiratory rate (RRR) is highly recommended once a day. The RRR should NOT EXCEED 30 breaths per minute (bpm). If the respiratory rate is greater than 30 bpm, or if there is a gradual increase (over a day or two) toward 30 bpm, the patient should be evaluated immediately for congestive heart failure and the appropriate treatment initiated.
- Recommend monitoring for progression with a re-evaluation of an echocardiogram every 6 to 8 months, or sooner if clinical signs develop.

INTERPRETED BY

Lisa Carioto, DVM,
DVSc, Diplomate
ACVIM

IMAGING PERFORMED BY

Shari Reffi, CVT

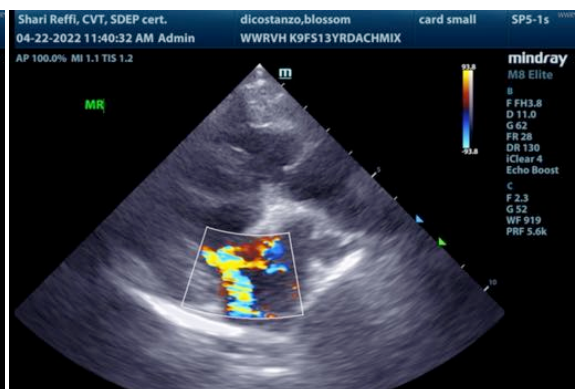
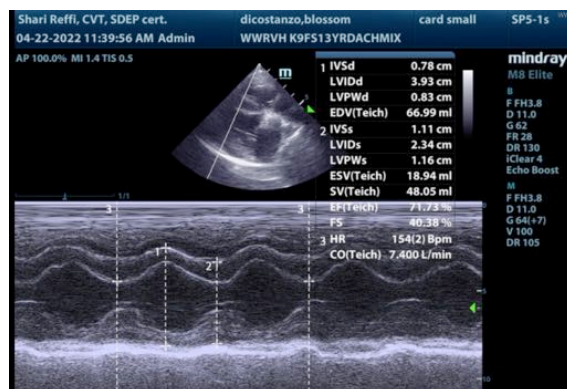
HOSPITAL NAME

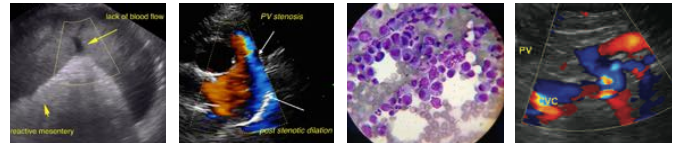
REFERRING VET

INVOICE

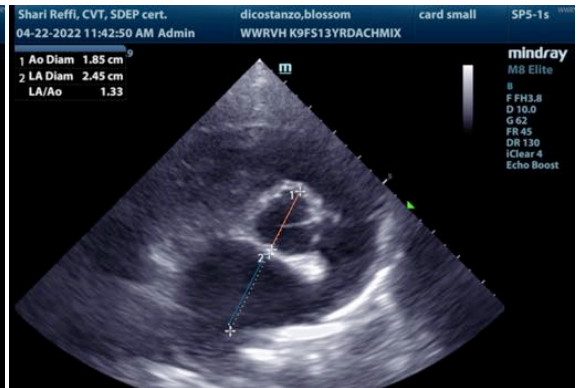
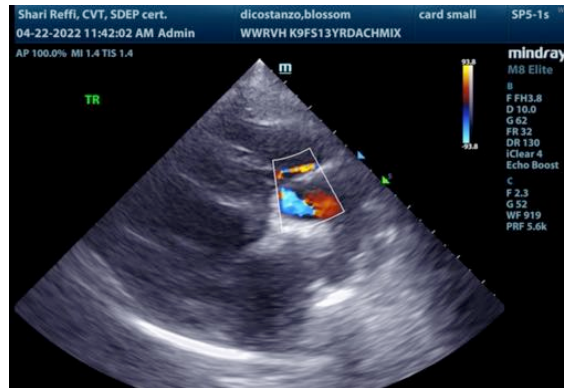
DATE

4/22/22





PATIENT



SPECIES

Canine

BREED

Dachshund Mix

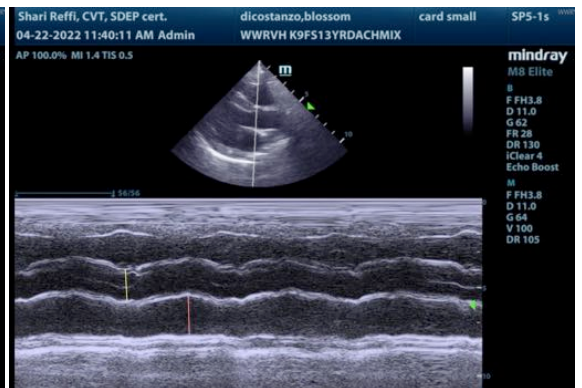
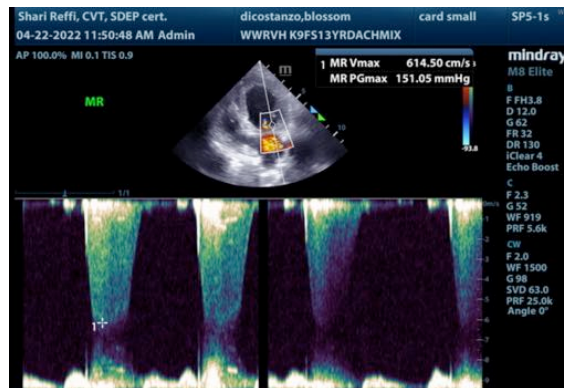
SEX

Spayed Female

AGE

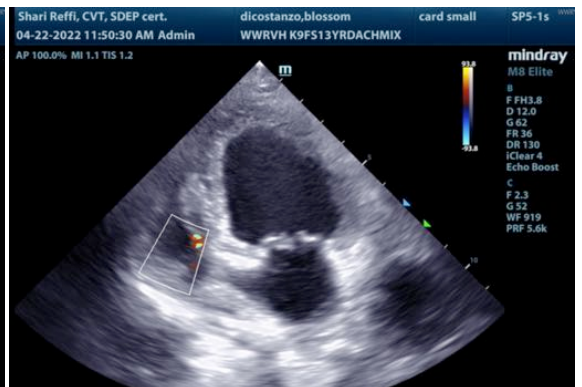
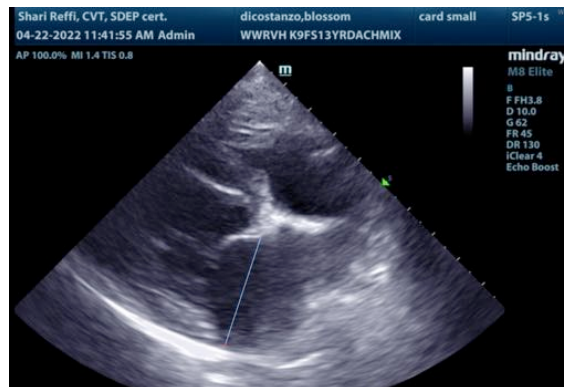
13 years

WEIGHT



INTERPRETED BY

Lisa Carioto, DVM,
DVSc, Diplomate
ACVIM

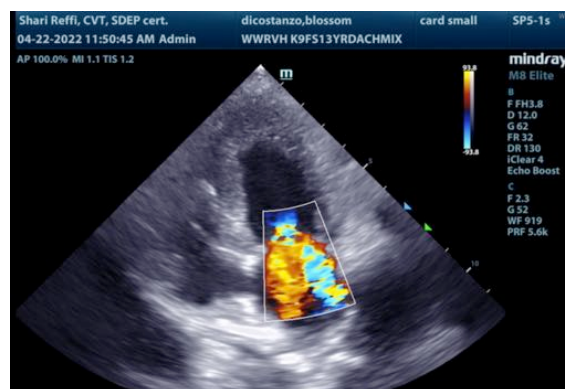


**IMAGING
PERFORMED BY**

Shari Reffi, CVT

HOSPITAL NAME

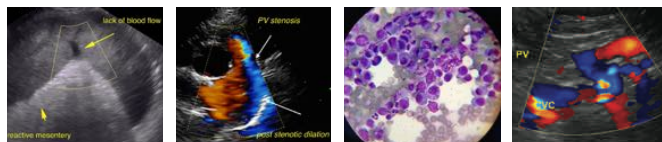
REFERRING VET



INVOICE

DATE

4/22/22



PATIENT The information and recommendations provided are based on the images presented by the referring veterinarian/sonographer. No evaluation can be communicated regarding pathology that was not visible in the image/video clips provided.

SPECIES Thank you for this referral. If the clinical or image interpretation does not parallel your findings or if I can be of any further assistance please contact me.

Canine **Lisa Carioto, DVM, DVSc, Diplomate ACVIM**

info@sonopath.com

BREED

Dachshund Mix

SEX

Spayed Female

AGE

13 years

WEIGHT

INTERPRETED BY

Lisa Carioto, DVM,
DVSc, Diplomate
ACVIM

**IMAGING
PERFORMED BY**

Shari Reffi, CVT

HOSPITAL NAME

REFERRING VET

INVOICE

DATE

4/22/22